

## CASE REPORT

# Tooth-supported Overdenture using Castable Ball and Socket Attachments

<sup>1</sup>Hemant K Sharma, <sup>2</sup>Narendra Padiyar, <sup>3</sup>Pragati Kaurani, <sup>4</sup>Devendra P Singh, <sup>5</sup>Sudhir Meena, <sup>6</sup>Ajay Gupta

## ABSTRACT

Dentists have a responsibility to prevent tooth loss whenever possible and everything should be done to keep the patient away from an edentulous state. Overdenture is defined as a removable partial denture or a complete denture that covers and rests on one or more remaining natural teeth, the roots of natural teeth, and/or dental implants (GPT-6). Whenever there is extraction of teeth, resorption of the bone takes place. When tensile stresses are applied on the bone like when occlusal forces are transmitted to the alveolus by the periodontal ligament, additional bone formation takes place. This principle is used in overdenture treatment. Preventive prosthodontics emphasizes upon the importance of procedures that can delay or rectify the future problems in a prosthesis and the overdentures are the optimum method to achieve this requirement. Advantages of overdenture are maintenance of alveolar bone, sensory feedback, minimal load threshold, reduction of psychological trauma, and intact tactile sensitivity discrimination. In this study, we will present a case report of overdenture treatment using castable ball and socket attachments.

**Keywords:** Ball and socket attachments, Castable, Tooth-supported overdenture.

**How to cite this article:** Sharma HK, Padiyar N, Kaurani P, Singh DP, Meena S, Gupta A. Tooth-supported Overdenture using Castable Ball and Socket Attachments. J Mahatma Gandhi Univ Med Sci Tech 2017;2(2):106-108.

**Source of support:** Nil

**Conflict of interest:** None

## INTRODUCTION

Overdenture, a complete or partial prosthesis fabricated over natural teeth, root structure, or implants, is not a very new prosthodontic concept. Indeed, it is nearly 100 years old and it has become increasingly more popular because of the special importance of prevention in dentistry. Preventive prosthodontics emphasizes on any procedure that can delay or eliminate future problems that occur in a prosthesis.<sup>1</sup>

Overdenture is defined as “a removable partial denture or complete denture that covers and rests on one

or more remaining natural teeth, the roots of natural teeth and/or dental implants” (GPT-6).

or

“A prosthesis that covers and is partially supported by natural teeth, natural tooth, roots, and/or dental implants.”<sup>1,2</sup>

## Rationale of Overdenture

Overdenture keeps remaining teeth as part of the residual alveolar ridge. This provides the patient a denture prosthesis that has far more support than any other conventional prosthesis.<sup>1,2</sup> It decreases the rate of residual ridge resorption. It has reported in several studies that retaining of the mandibular canines to support an overdenture reduces the resorption of the alveolar bone by eight times.

An increase in the patients’ manipulative skills of handling denture is also seen. It also preserves the periodontal membrane and the proprioceptive impulses.<sup>1-3</sup>

## INDICATIONS<sup>1-3</sup>

- Indicated for patients who are facing loss of the remaining natural dentition
- Indicated where the retention is difficult to achieve, such as:
  - Xerostomia cases (lack of saliva)
- Cases where residual alveolar ridge is severely resorbed
- Partial loss of maxillary and mandibular bone
- Congenital deficiencies, such as cleft palate.
- Indicated where patients are likely to have compromised retention
- Patients with high arch palate and ridge slope
- Where tongue does not provide lingual seal
- Indicated in knife edge mandibular ridge cases
- Indicated where vertical overlap of anteriors for good esthetics is desired
- Unilateral overdenture can be a choice of treatment when there is loss of large bony amount on one side of a residual arch

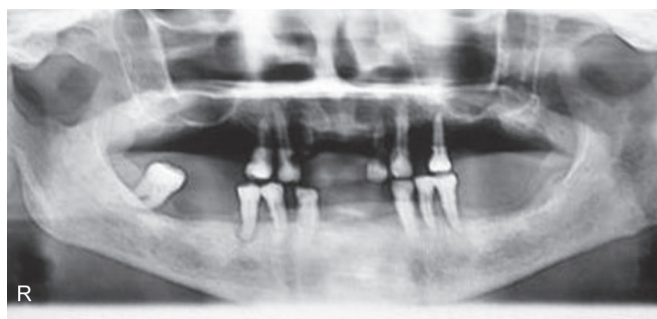## CONTRAINDICATIONS<sup>1-3</sup>

- Patients with uncooperative behavior and less motivated patients who prefer removal of their remaining teeth

<sup>1</sup>Assistant Professor, <sup>2</sup>Professor and Head, <sup>3</sup>Professor  
<sup>4,5</sup>Reader, <sup>6</sup>Senior Lecturer

<sup>1-6</sup>Department of Prosthodontics, Crown and Bridge, Mahatma Gandhi Dental College and Hospital, Jaipur, Rajasthan, India

**Corresponding Author:** Hemant K Sharma, Assistant Professor, Department of Prosthodontics, Crown and Bridge Mahatma Gandhi Dental College and Hospital, Jaipur, Rajasthan India, e-mail: hemantsharma7@yahoo.com



**Fig. 1:** Preoperative radiograph of patient

- Patient with poor oral hygiene
- Patients who do not prefer removal prosthesis
- Mentally challenged and physically handicapped patients who cannot maintain good oral hygiene

## CASE REPORT

A 65-year-old male patient visited the Prosthodontics Department complaining of inability to eat due to missing posterior teeth and mobility of remaining teeth.

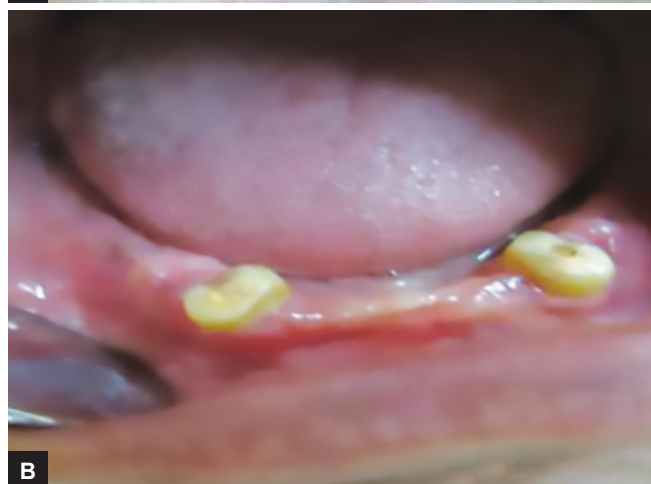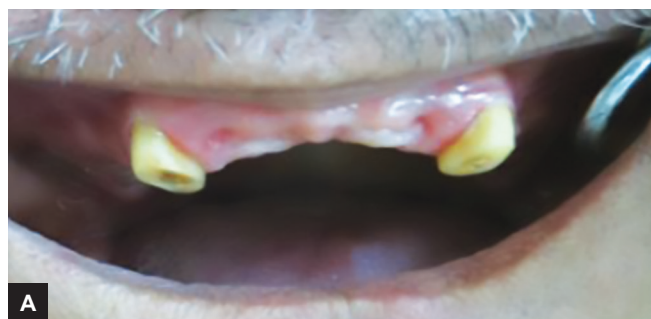On preoperative examination, panoramic radiographs revealed 13, 14, 22, 23, 25, 33, 34, 35, 43, 44, 45, 48 were present, among which mobility was present i.r.t. 14, 22, 45, 48 and 13 and 22 were found carious (Fig. 1).

Treatment options discussed were:

- Conventional complete denture
- Conventional overdenture
- Immediate denture
- Immediate overdenture
- Overdenture with attachments

The entire treatment was planned and divided into three stages:

1. Surgical phase: Extractions were performed for 14, 22, 25, 34, 35, 44, 45, and 48.
2. Endodontic phase: Root canal treatment was performed for 14, 25, 34, 44.
3. Prosthetic phase: After 7 days of completion of root canal treatment teeth were reduced to receive custom-made post and core copings with ball and socket attachments in following steps:
  - Preliminary impressions were made using alginate impression material.
  - Teeth were prepared.
  - Post and core patterns were made with pattern resin, and plastic pattern of ball and socket attachments was attached and casted.
  - Castings were retrieved, finished, and cemented.
  - Final impressions were made and jaw relation was performed.
  - Bilaterally balanced teeth arrangement was done and dentures were tried-in.



**Figs 2A and B:** Overdenture abutments

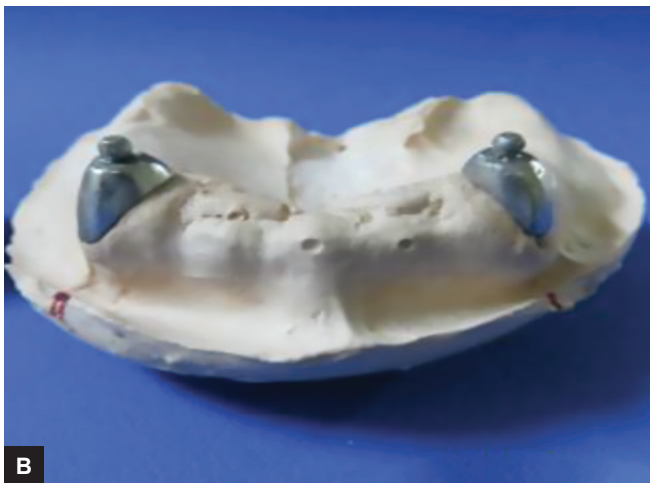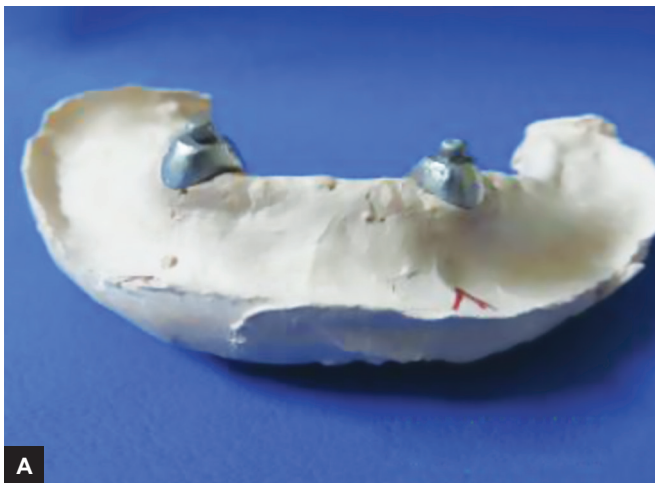
- Dentures were acrylicized and female attachments were attached to the dentures.
- After attachments of the dentures were finished and polished, postinsertion instructions were given (Figs 2 to 5).

## Advantages of using Ball and Socket Attachments<sup>2,4</sup>

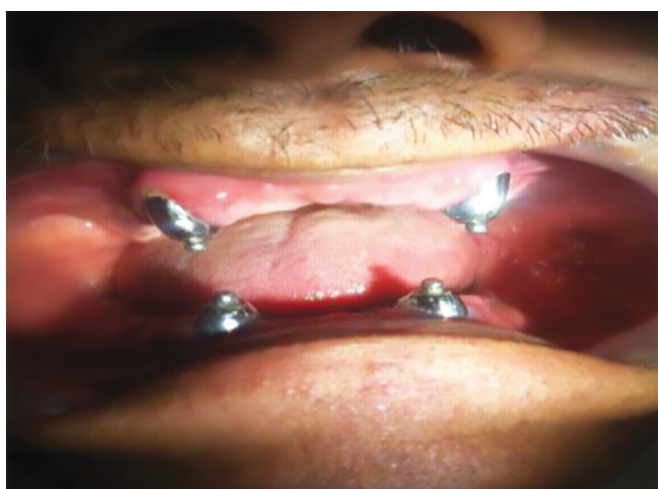- Their overall length varies between 3.3 and 3.7 mm (spherical), so it is suitable for short intraocclusal spaces.
- It provides firm, definite retention.
- It can be processed into the overdenture in the laboratory or mounted in the mouth using autopolymerizing resin.
- It is less expensive.
- Parallelism of the spherical Bona is less critical than that of the cylindrical Bona.
- The male posts can be duplicated as resin patterns. These can be mounted on coping patterns and cast as a single unit.

## DISCUSSION

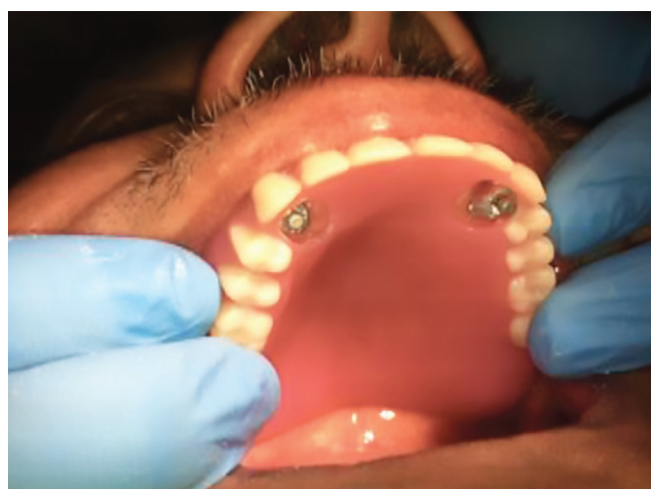The success of an overdenture prosthesis primarily depends upon selection of a right patient for performing a careful mode of treatment that satisfies both patient and doctor. Various techniques are there for restoration of the lost dentition using overdentures, namely tooth modification and reduction, tooth reduction with cast



**Figs 3A and B:** Ball and socket attachments after finishing



**Fig. 4:** Ball and socket attachments cemented



**Fig. 5:** Evaluation of dentures for female part attachment

coping, endodontic therapy followed by cast coping, and endodontic therapy followed by some form of attachment. The decision of using attachments is made for selective patients having significant amount of bone loss and desires improvement in retention.<sup>5</sup>

In this case, selection was made for the ball and socket type of attachments. These attachments consist of male ball part, which is usually a post extending into the endodontically treated tooth. Fixation assembly is achieved with the help of female component which is in the form of ring placed on the tissue side of the denture. The primary reasons for selection of this type of attachment are its simplicity, ability to withstand occlusal forces efficiently, and single-visit application of the attachment.<sup>4,5</sup>

**CONCLUSION**

Overdenture treatment option has become a popular rehabilitation method in modern-day dentistry. Its

application is limitless and should be encouraged. The failures that happen in this therapy are only due to the improper case selection and poor maintenance. Better results and success rates are assured with more learning of these techniques.

**REFERENCES**

1. Winkler S. Essentials of complete denture prosthodontics. 2nd ed. India: AITBS Publishers; 2000. pp. 384-402.
2. Preiskel HW. Overdentures made easy: a guide to implant and root supported prosthesis. 1st ed. London: Quintessence Publishing Co Ltd.; 1996.
3. Fenton AH. The decade of overdenture: 1970-1980. J Prosthet Dent 1998 Jan;79(1):31-36.
4. Bansal S, Aras MA, Chitre V. Tooth supported overdenture retained with custom attachments: a case report. J Indian Prosthodont Soc 2014 Dec;14(Suppl 1):283-286.
5. Khajuria RR, Singh R, Priyanka. Overdenture with ceka preci-clix attachments a case report. Ann Dent Specialty 2014 Jul-Sep;2(3):108-109.